



A WORLD LEADER IN ORTHODONTIC APPLIANCES

NITE-GUIDE®

Straighten Teeth While
Your Child Sleeps

FOR 5 TO 7 YEAR OLDS



*This amazing procedure can
prevent your child from developing
severe future dental problems.*

A WORD TO PARENTS ABOUT THIS BOOKLET . . .

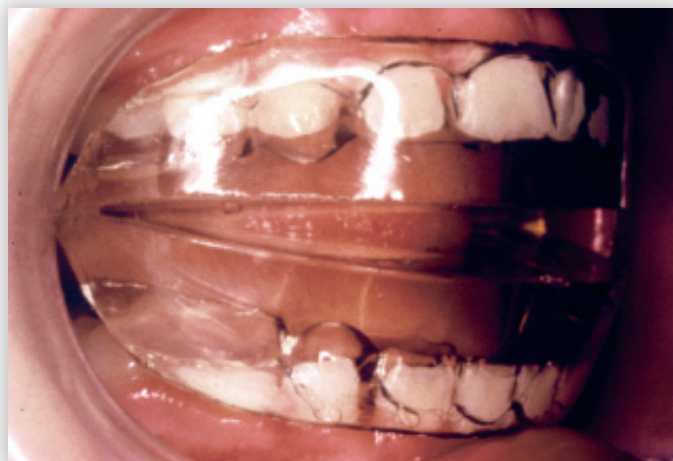The purpose of this booklet is to inform you of a method of straightening teeth called Nite-Guide®. It will be helpful for you to become aware of the Nite-Guide®* technique (consisting of two appliances, the Nite-Guide® and the Occlus-o-Guide®) which may prevent such dental problems as crooked teeth, buck teeth, open-bite and overbite in 5 to 7 year old children, just while they sleep.** Should you have any additional questions regarding this technique, ask your doctor.

2 OUT OF EVERY 3 CHILDREN NEED ORTHODONTICS^{13,18,26 †}
— OVER 50% OF THESE CAN BE HELPED WITH
THE NITE-GUIDE® TECHNIQUE!^{13,26,28 †}

A child may be a candidate for this treatment if he/she has:

- Crowded and rotated teeth
- Overjet (buck teeth)
- Open-bite (opening between upper and lower teeth)
- Overbite (upper teeth cover lower teeth)

NITE-GUIDE® CAN DRAMATICALLY IMPROVE A PROFILE AND ALSO PREVENT THE DEVELOPMENT OF MALOCCLUSIONS.



WHAT IS NITE-GUIDE®?

Nite-Guide® is a comfortable, soft plastic appliance that can straighten a 5 to 7 year old child's permanent front teeth as they erupt into the mouth by using natural dental eruptive forces. The appliance can help eliminate buck teeth (overjet), crowding, overbite (where the upper front teeth cover most or all of the lower front teeth when the child closes his/her jaws) and open-bite (stops thumb-sucking in 20% or more). This can be achieved by wearing the Nite-Guide® only while sleeping.^{8,20,21,28} What could be easier?



WHY IS IT SO IMPORTANT FOR A PARENT TO KNOW ABOUT THE NITE-GUIDE® APPLIANCE?

About 4 out of every 5 children will experience one or more dental problems, such as crowding, rotated teeth, overjet and overbite as their adult teeth begin to come into the mouth.^{2,4,23,28,33,34} By using the natural forces of eruption, the Nite-Guide® appliance can guide adult front teeth into their proper positions and help eliminate crowding, rotations, overjet (buck teeth) and open-bites.^{8,20,21,28}

Once a child's adult teeth have been guided by the appliance into their proper positions and have fully erupted, adult periodontal fibers that anchor these teeth to bone, soft tissue and to other teeth, form around the roots and lock them into the correct occlusion.^{31,37} This normally prevents these new teeth from relapsing. Also, relapse is frequently avoided because sufficient facial and jaw growth is present³⁵ when the Nite-Guide® procedure is started at this early age, which helps to ensure that the correction will remain stable in the future.

Postponing treatment until a later age (11 to 14 years), when most of the adult teeth have fully erupted and the fibers have locked in the malocclusion, frequently results in relapse.^{25,35} At this later age, there is also less growth left for the child, which is necessary to stabilize most orthodontic corrections.^{5,10,35}

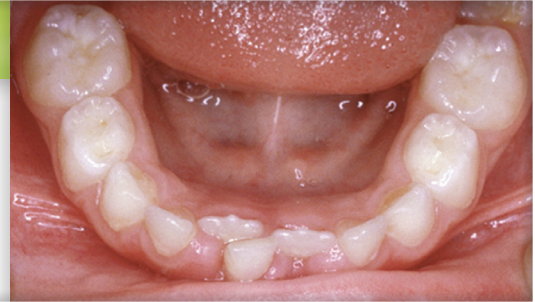During the first years of school, those children that appear to be "different" because of some aspect of their physical appearance may become a target for teasing or other abuse, which can decrease their developing self-confidence. The Nite-Guide® treatment, which helps to eliminate crowded teeth, buck teeth and an open-bite, can help to give the child a normal dental appearance and improve his or her profile.^{20,21,28}

Let us show you examples of results obtained when using the Nite-Guide® only while sleeping. Perhaps your child resembles one of these children.

CASE HISTORY: POTENTIAL CROWDING

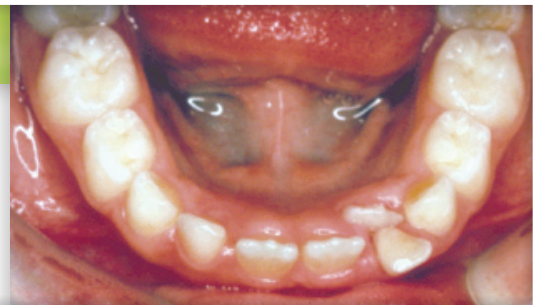
BEFORE

Although 90 out of every 100 children will have straight baby teeth,^{2,18} 60 of every 100 children will have crooked adult front teeth^{2,13} and they usually remain that way into adulthood.^{2,22} Crowding is a frequent cause of gum disease^{27,30} and decay.



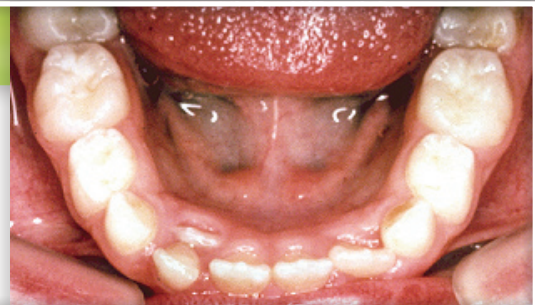PROGRESS (4 months)

After 4 months of Nite-Guide® wear, only while sleeping, the two front teeth are guided into their proper positions.



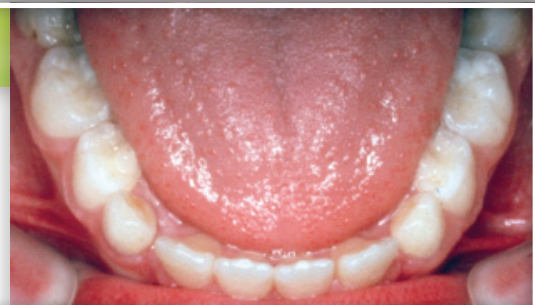PROGRESS (6 MONTHS)

After 2 more months of wear, only while sleeping, the Nite-Guide® is guiding the side teeth (lateral adult incisors) into their proper positions.



AFTER

Because the natural forces of these erupting teeth have enlarged the jaws, the Nite-Guide® has allowed these adult teeth to be guided in straight.



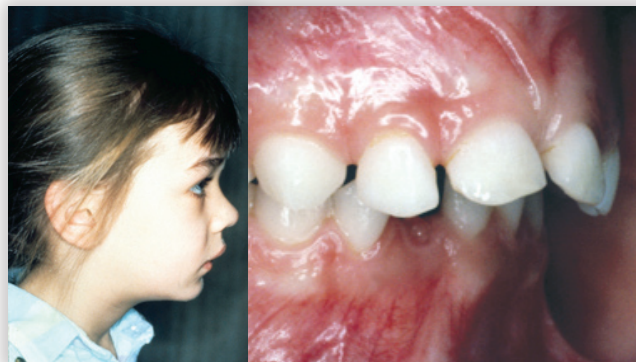RECOMMENDATION:

Each adult front tooth is usually larger than its corresponding baby tooth.²⁹ If it comes in crooked or behind the baby tooth, it cannot exert the force on the jaw to adequately expand the jaw, which is required for adult teeth to come in straight.²³ Crowding compounds itself as each successive erupting adult tooth attempts to squeeze into the limited space of the unexpanded jaw.^{1,29} The Nite-Guide® appliance is designed to ensure natural jaw expansion and to allow teeth to erupt in straight. Timing is important, since this natural expansion only occurs once in a child's lifetime.²⁹ An exam at 4 to 5 years of age is recommended.

CASE HISTORY: EXCESS OVERJET

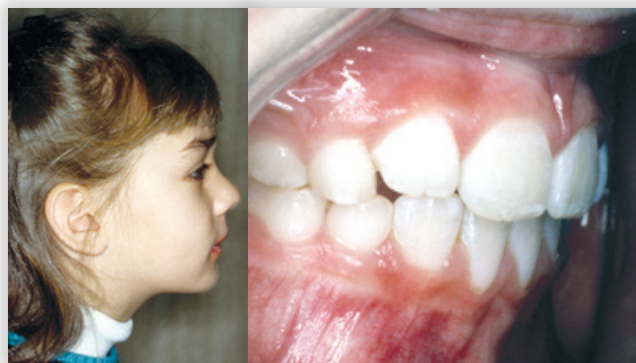BEFORE

The horizontal jaw discrepancy called overjet is frequently due to the upper jaw being too far forward and/or the lower jaw being too far back. This condition is often made worse by persistent thumb-sucking past 5 years of age. It is also associated with periodontal and other jaw problems.³⁰



AFTER

The overjet usually corrects within 4 to 10 months and should be started when the lower front adult teeth start erupting (or 4 to 6 months earlier, in more severe cases). This patient wore the appliance only while sleeping to obtain this result.



RECOMMENDATION:

The Nite-Guide® can correct up to a 3/4 inch jaw discrepancy, as in this case, with wear only while sleeping.²⁸ More severe cases might require some daytime exercise or braces.

CASE HISTORY: POORLY POSITIONED FRONT TEETH

BEFORE

When the front teeth are not positioned vertically, it is unattractive and is unhealthy for the supporting tissues. This is caused by the overeruption of the adult front teeth. Once these front teeth have overerupted, generally by 8 years of age, more complicated treatment measures, such as braces or surgery, may be required to correct this problem.

This photo shows the child's partially hidden upper teeth due to overerupted baby teeth.



AFTER

The Nite-Guide® stopped the overeruption of the front teeth to naturally center these teeth vertically. The Nite-Guide®, worn only while sleeping, attained the proper eruption level of these front teeth.



RECOMMENDATION:

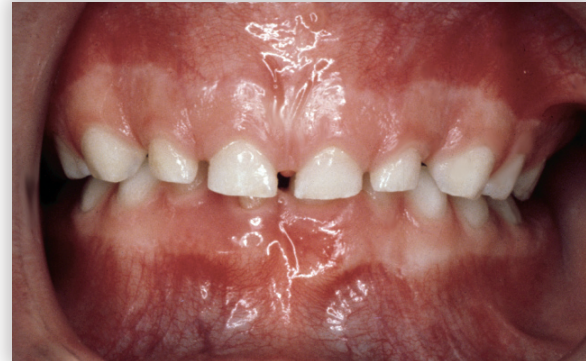Treatment should begin as soon as the patient's front adult teeth begin to erupt (primarily lower front adult teeth), at about age 5 to 6. Upper front teeth partially hidden by the lower lip in the baby dentition is usually a sign that the child will have a similar or worse condition as an adult.

CASE HISTORY: EXCESS OVERBITE

BEFORE

Overbite is the most common orthodontic problem that causes looseness and loss of front teeth.¹⁹ It is also highly associated with poor jaw function and, at times, with periodontal problems.³⁰ Overbite is present when the upper front teeth cover most or all of the lower teeth, usually caused by excessive eruption.

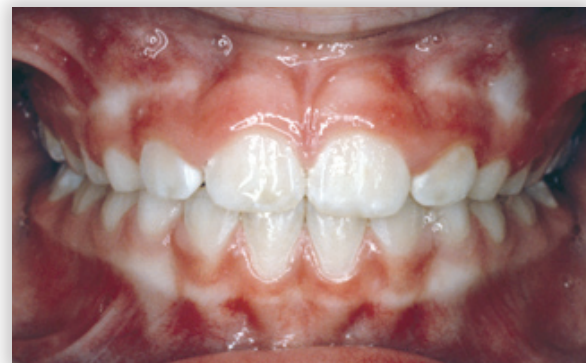An overbite present in the baby dentition will increase about 1/8 inch when the adult front teeth erupt (in about 88% of cases).²⁸



AFTER

The Nite-Guide® appliance, worn only while sleeping, prevented the overeruption of the front adult teeth and resulted in an ideal overbite.

The patient wore the Nite-Guide® only while sleeping, to control the downward excessive eruption of the upper adult front teeth. This prevented an overbite from development.



RECOMMENDATION:

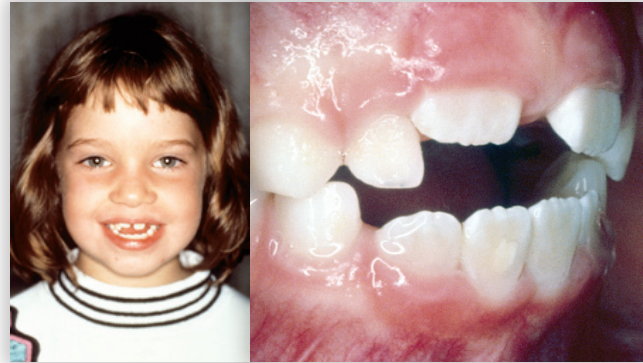
Treatment should ideally begin as the lower front adult teeth first erupt into the mouth (age 5 to 6 years), but can still be treated successfully even though a few of the front adult teeth are already present in the mouth.²⁸

CASE HISTORY: OPEN-BITE

BEFORE

The opening that appears in the front of the mouth when the jaws are held together is called open-bite. It should be corrected when the adult front teeth first erupt, or earlier. It is frequently caused by thumb-sucking.

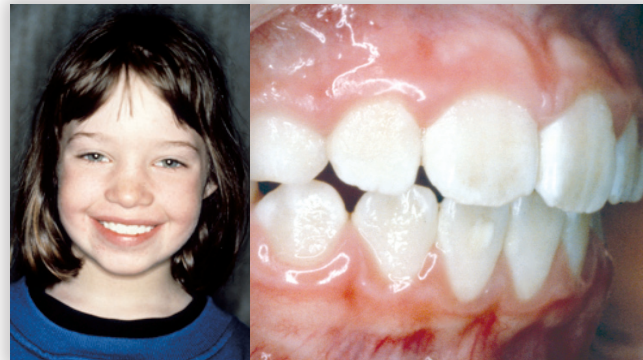An open-bite, not corrected when the front adult teeth first erupt, becomes a very difficult orthodontic problem to correct, and to retain if treated at a later age.



AFTER

The Nite-Guide® can correct thumb-sucking in about 20% or more of children.²⁸ In persistent thumb-suckers, it is used in conjunction with an anti-sucking device to guide the erupting adult teeth into place.

This case substituted the Nite-Guide® for the thumb and wore the appliance also while sleeping.

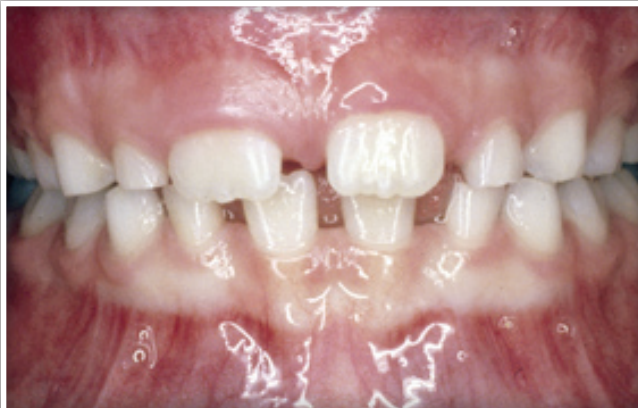

RECOMMENDATION:

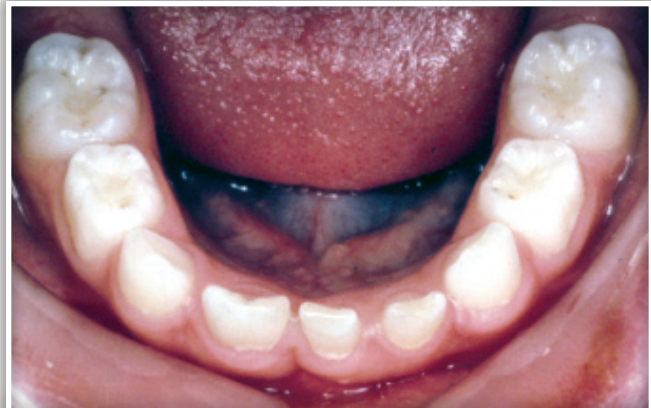The Nite-Guide® can correct an open-bite without an additional anti-sucking device in about 20% or more of cases. The appliance allows the new front adult teeth to erupt into place as the thumb-sucking is corrected.

OTHER PROBLEMS:

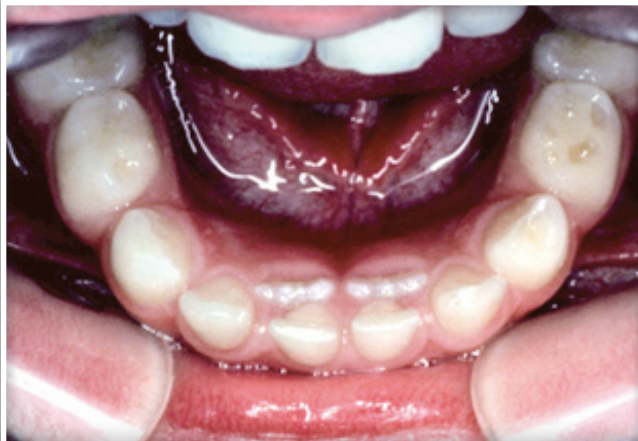Consult your dental professional for advice if you become aware of any of the following problems in your child's mouth: excessive spacing, misshaped teeth, missing teeth, poorly erupting adult teeth and rotated or crowded teeth. These problems may be helped with the use of the Nite-Guide® and/or the Occlus-o-Guide® appliance.^{8,20,21,28}



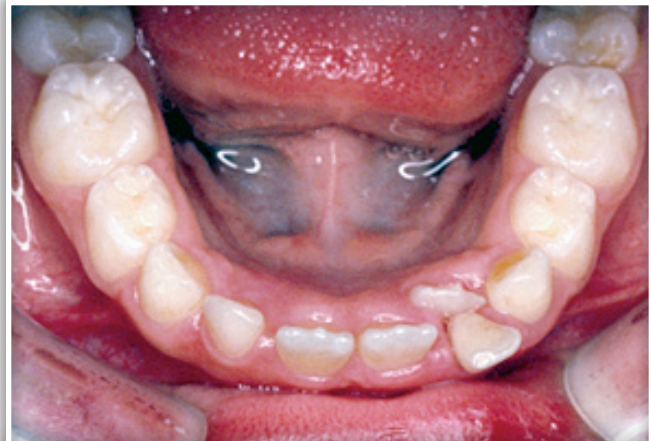**EXCESS SPACES BETWEEN FRONT
ERUPTING PERMANENT TEETH**



**DOUBLE-SIZED BABY TOOTH AND
MISSING BABY TOOTH**



POORLY ERUPTING ADULT TEETH

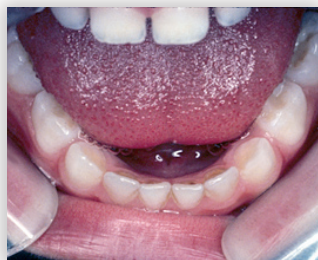

ROTATED OR CROWDED TEETH

RECOMMENDATION:

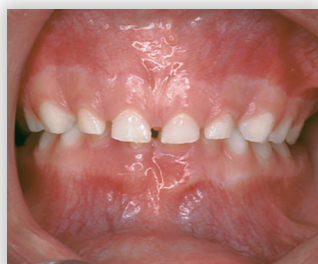Many of these problems can be corrected or prevented with the use of the Nite-Guide® and Occlus-o-Guide® appliances.

What Are The Things You Should Look For In Your Child's Teeth?



1. Does your child have straight front baby teeth that are lined up right next to one another, with little or no space between?

Lack of spaces between the baby teeth at 5 or 6 years of age prevents the larger adult front teeth from coming in straight, and ordinarily forces them to come in rotated and crowded.^{1,3,22} These erupting teeth then fail to exert force against adjacent baby teeth, thereby causing a lack of sufficient jaw expansion, which is necessary for straight teeth.²⁹ The Nite-Guide® encourages adequate jaw expansion,^{8,28} which helps the teeth to come in straight.



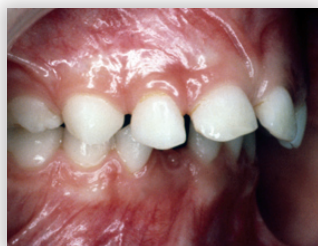2. When your child closes his/her teeth together, do you see only (or mostly) upper teeth, and very little of the lower front teeth?

If this is the case, your child has a deep overbite, which will become worse in over 80% of such children,^{28,29} if left uncorrected. Overbites can cause looseness and loss of front teeth,¹⁹ periodontal problems,³⁰ and poor jaw function.^{24,26} Do you or your spouse have such problems? Overbite is strongly hereditary, and the best time to correct it is when a child is young, while sufficient facial growth remains.³⁵



3. Are your child's upper teeth partially hidden by the lower lip?

Do any of your child's relatives have a similar problem? This is an indication that your child might have overerupted upper incisors. It is so easy to prevent or alleviate this problem at this age, with just nighttime wear of the Nite-Guide®, and difficult to correct when your child becomes 8 years of age or older.



4. Does your child have buck-teeth, which is also called overjet?

This is often caused by a thumb-sucking habit (beyond 5 years of age). Many times the front teeth will self-correct when the habit is stopped by 4 to 5 years,³³ but if the teeth are still bucked by 6 years of age, it is an indication that the Nite-Guide® is needed. For resistant habits, an additional Habit-Corrector® appliance may be required at the same time to correct the habit.

The benefits of Nite-Guide® treatment for your child are enormous. It is so much easier to prevent a problem than to correct it once it becomes entrenched. Nite-Guide® can provide an easy, natural way to obtain an ideal dentition, and lets your child enjoy good-looking, straight teeth at an early age (6 to 8 years). Think of how helpful good-looking teeth are for your child's self-esteem and psychological well-being at this most formative period in their early life.

The Following Questions and Answers Most Often Asked by Parents:

Q. WHY SHOULD MY CHILD HAVE EARLY PREVENTIVE TREATMENT OF FUTURE DENTAL PROBLEMS?

- A. As adult teeth begin to erupt, the fibers that attach these teeth to surrounding bone and soft tissue are not yet mature.³⁷ During the next 6 months following the tooth's full eruption, these fibers gradually join together, forming a mass of connecting fibers that lock the new tooth in place.³⁷ Nite-Guide® patients' teeth are normally guided into an ideal occlusion, so that when these fibers develop, they "lock" in the correct occlusion. If treatment is postponed until age 11 or 12, the fibers will have already locked in the malocclusion. Braces are then required to stretch these fibers, but because these fibers have a memory, there is a tendency for these straightened teeth to relapse back to their original positions.^{14,25,31}

Growth also plays an important role in achieving a stable correction.³⁵ By age 11 or 12, very few years of growth remain.⁵ This is especially true in the case of females.¹⁰ If the remaining growth is not sufficient to compensate for the correction, then relapse becomes a significant problem.³⁵ It is therefore essential, particularly in severe cases, to start corrections at an early age in order to prevent relapse.

Nite-Guide® is designed to prevent the upper front adult teeth from overerupting, which can prevent a developing overbite.²⁸ If these teeth are allowed to overerupt, the problem becomes very difficult to correct, and will usually require braces or even surgery. The use of the Occlus-o-Guide® can prevent excessive overbites in the adult dentition and can reduce the risk of poor jaw function.^{8,15,28}

Q. WHAT CAN HAPPEN IF MY CHILD'S DENTAL PROBLEMS GO UNTREATED?

- A. While buck-teeth (overjet), overbite and crooked teeth can detract from a person's appearance, crowded teeth can trap food in the crevices and can cause decay and periodontal disease.^{27,30} Overbite (when the upper front teeth cover most or all of the lower teeth) can directly affect the future health of the dentition by causing looseness and loss of the front teeth.¹⁹ Looseness of front teeth can cause pockets to form under the gumline, allowing food to collect, which can encourage infections to occur (periodontal disease). A severe overbite can make chewing very difficult, and at times painful, frequently resulting in more severe problems when left untreated in the adult dentition.

Q. WILL THE TEETH CORRECT THEMSELVES? DOES IT PAY TO WAIT AND SEE IF ORTHODONTIC TREATMENT IS NECESSARY LATER?

- A. Occasionally, one aspect of a child's occlusion (such as the "ugly duckling stage," where the front teeth are spread out) improves.¹² However, most children have several dental problems present at the same time,³⁰ with little or no chance for all problems to self-correct spontaneously.³⁴ Furthermore, there is overwhelming evidence in the orthodontic literature that the major factors in malocclusions (crowding, rotations, overjet, overbite, cross-bites and jaw relations) generally do not self-correct, and usually either stay the same or get worse over 75% of the time.^{28,34} This often makes corrective treatment more difficult at a later age.

Q. WOULD EARLY PREVENTION OR TREATMENT HAVE ANY ADVERSE EFFECTS ON MY CHILD?

- A. Results from research on the use of the Nite-Guide® appliances (Nite-Guide® and Occlus-o-Guide®) worn passively have indicated no adverse or negative effects on the root, bone development or facial growth of the child.²⁸

Q. WHEN IS THE IDEAL TIME FOR MY CHILD TO HAVE A PREVENTATIVE CHECK-UP FOR THE NITE-GUIDE® PROCEDURE?

- A. This procedure is usually best timed with the loss of the first lower front baby tooth. Sometimes there are exceptions to this timing for corrections such as severe overjets and thumb-sucking.²⁸ It is therefore advisable to have your child's first exam at about 4 to 5 years of age.

Q. CAN YOU PREDICT AT AGE 5 WHAT A CHILD'S TEETH ARE GOING TO LOOK LIKE AT 12 YEARS OF AGE?

- A. The appearance of the teeth can be predicted.^{2,3,4,28,29} Most aspects of malocclusions (overbite, jaw relationship, cross-bite, crowding and overjet) stay the same or get worse in over 75% of individuals from 5 to 12 years of age.^{4,9,34} External forces, such as thumb-sucking, when still present after 5 or 6 years of age, will probably cause permanent damage that usually does not self-correct when the habit is stopped.

Q. IS PREVENTION AT AGE 5 EASIER OR LESS COMPLICATED THAN FULL TREATMENT AT A LATER AGE? IS IT COVERED BY INSURANCE?

- A. One of the greatest advantages of the Nite-Guide® treatment is that many of the child's dental problems can be corrected while sleeping.²⁸ Therefore, this preventive program is considerably less complicated (than waiting until 12 years of age). Insurance usually covers the procedure, provided there is an orthodontic clause in your policy. (Coverage at a later age is also usually not a problem, provided there is a percentage allowance or a fixed claim amount that has not been used up.)

Q. WHAT DO I LOOK FOR IN MY 4 TO 5 YEAR-OLD CHILD'S MOUTH TO INDICATE THAT HE/SHE IS A CANDIDATE FOR THE NITE-GUIDE®?

- A. It is important to look for several things:
1. **Overjet** - (buck-teeth or receding lower jaw) where the upper teeth extend 1/8 inch or more in front of the lower teeth.
 2. **Crowding** - even though your child's baby teeth are straight, if they are lined up right next to each other with no spaces between them, there is a good chance that the adult front teeth, which are usually larger than baby teeth, will come in crowded or rotated.^{1,2,3} Another indication for Nite-Guide® treatment is if the adult teeth erupt in back of the baby teeth.
 3. **Overbite** - if your child's upper front teeth cover or hide almost half or most of the lower front teeth when he/she closes the jaws together.
 4. **Poorly positioned upper front teeth** where they are partially hidden by the lower lip.
 5. **Open-bites** can be a problem if an opening exists between the upper and lower front teeth when your child tries to close his/her teeth together. Also, any thumb or finger-sucking habit that persists beyond 5 years of age, especially if the habit occurs during the day, should be corrected.
 6. A **cross-bite** may exist if the teeth on one side do not bite in the identical manner as they do on the other side. Cross-bites exist if your child's upper and lower teeth mesh on one side of the mouth, but fail to mesh together in a similar manner on the opposite side.

Q. HOW LONG WILL THE NITE-GUIDE® PREVENTION TECHNIQUE TAKE WHEN DONE AT THIS YOUNG AGE?

- A. The average period of wear is 2 years, and usually requires 2 appliances.²⁸ The second appliance (Occlus-o-Guide®) is usually worn for an additional 6 months beyond full eruption of the four upper and lower front adult teeth, to allow the fibers to completely form and stabilize their new positions.^{31,37} It is then worn periodically as a retainer until most of the adult teeth erupt.

Q. IS IT DIFFICULT FOR A YOUNG CHILD TO WEAR THE APPLIANCE WHILE SLEEPING? WON'T IT FALL OUT AT NIGHT?

- A. Most children (72.5%) will keep the appliance in all night after 3 weeks, while those remaining children who are unable to keep it in at night, wear it one or two hours passively each day to get a satisfactory result. Children wearing the appliance during the course of treatment have reported little or no pain.²⁸

Q. HOW WELL WILL THE TEETH HOLD THEIR POSITIONS COMPARED TO OTHER METHODS OF ORTHODONTICS DONE AT A LATER AGE?

- A. The retention of corrections obtained with the Nite-Guide® technique at this age should be more stable and less prone to relapse because of the fibers that form around these newly erupted adult front teeth that help hold and “lock-in” the correction.^{31,37} The risk of relapse is also reduced because the procedure is done at an early age, when there should be sufficient facial growth remaining to stabilize the result.^{21,35}

Q. WHAT ARE MY CHILD'S CHANCES OF NEEDING BRACES AFTER THIS PREVENTIVE WORK IS DONE? DON'T BRACES MAKE THE TEETH PERFECT?

- A. About 20% or less of children may require additional, limited orthodontics (braces) to perfect the angulation and rotations of teeth.^{7,8,20} In such cases, however, the treatment period with braces usually occurs at an early age so that the child can enjoy straight teeth while growing up.

Q. IS IT DIFFICULT FOR A CHILD THIS YOUNG TO COOPERATE ENOUGH TO WEAR SUCH AN APPLIANCE?

- A. It was found in a recent study by a leading university that 93.4% of the young children accepted and wore the appliance to obtain a successful result.²⁸ Children, however, with persistent thumb-sucking habits, will often require an additional appliance to obtain a successful result.

* The Nite-Guide® Appliance must be fitted by a qualified dental professional and is appropriate where diagnostic criteria of malocclusion, the child's stage of dental development, and other factors are met.

** With the Nite-Guide® method, braces may be needed as a supplement in certain cases. Limited day-time use of the Nite-Guide® appliance is necessary only in unusual cases (5-10%).

† See references on pages 14 and 15.

IMPORTANT NOTE:

This booklet should not be relied upon for diagnostic purposes of individual cases. For individual cases, a dental professional must provide an examination, take certain records, and provide a diagnosis and explanation for the candidate or patient. It is also stressed that the contents of this booklet do not constitute representations or warranties regarding the Nite-Guide®* or Occlus-o-Guide® appliance or related techniques or regarding particular performance or results.

The noted statements in this Nite-Guide® Technique booklet are based on the following research studies:

1. Atkinson, S.R., Jaws out of balance, Part I. Am. J. Orthod., 52: 47-55, 1966.
2. Barrow, G.V. and White, J.R., Developmental changes of the maxillary and mandibular dental arches. Angle Orthod., 22: 41-46, 1952.
3. Baume, L.J., Physiological tooth migration and its significance for the development of occlusion. I. The biogenetic course of the deciduous dentition. II. The biogenesis of accessional dentition. III. The biogenesis of the successional dentition. IV. The biogenesis of overbite, J. Dent. Res., 29: 123-132, 331-337, 338-348, 440-447, 1950.
4. Benediktsson, E., Über den Entwicklungsablauf des Gebisses bei der Progenie und Kreuzbisz, Inaugural Dissertation, Rheinischen Friedrich-Wilhelms-Universität, Bonn, 1938.
5. Bergersen, E.O., The male adolescent facial growth spurt: Its prediction and relation to skeletal maturation, Angle Orthod., 42: 319-338, 1972.*
6. Bergersen, E.O., The eruption guidance myofunctional appliance in the consecutive treatment of malocclusion, Gen. Dent., 34: 24-29, 1986.*
7. Bergersen, E.O., Preventive and interceptive orthodontics in the mixed dentition with the Myofunctional Eruption Guidance Appliance: Correction of overbite and overjet, J. of Pedodont., 12: 292-324, 1988.*
8. Bergersen, E.O., Preventive and interceptive orthodontics in the mixed dentition with the Myofunctional Eruption Guidance Appliance: Correction of crowding, spacing, rotations, cross-bites and TMJ, J. of Pedodont., 12: 386-414, 1988.*
9. Bergersen, E.O., A longitudinal study of anterior vertical overbite from eight to twenty years of age, Angle Orthod., 58: 237-256, 1988.*
10. Bergersen, E.O., Research data, unpublished to date.*
11. Bernal, M. and Tsamtsouris, A., Signs and symptoms of temporomandibular joint dysfunction in 3 to 5 year old children, J. of Pedodont., 10: 127-140, 1986.
12. Broadbent, B.H., A new x-ray technique and its application to orthodontia, Angle Orthod., 1: 45-66, 1931.
13. Cryer, B.S., Lower arch changes during the early teens, Trans. Europ. Orthod. Soc., 41st. Cong. 87-99, 1965.
14. Edwards, J.G., A surgical procedure to eliminate rotational relapse, Am. J. Orthod., 57: 35-46, 1970.
15. Egermark - Ericksson, I., Mandibular dysfunction in children and individuals with dual bite, Swedish Dent. Jour., 10: (Suppl. 1-45), 1982.
16. Egermark - Ericksson, I., Ingervall, B. and Carlsson, G.E., The dependence of mandibular dysfunction in children on functional and morphologic malocclusion, Am. J. Orthod., 83: 187-194, 1983.
17. Foster, T.D. and Grundy, M.C., Occlusal changes from primary to permanent dentition, Brit. J. Orthod., 13: 187-193, 1986.
18. Heckman, U., A longitudinal study of dental development in 82 children from birth to 12 years of age, Trans. Europ. Orthod. Soc., 49th. Cong., 259-265, 1973.
19. Kalamkarova, S.K., Periodontal tissue function in deep-bite in adults, Stomatologia (Mosk.), 65 (2): 76-78, (Engl. Abstr.), 1986.

20. Keski-Nisula, K., Hernesniemi, R., Heiskanen, M., Keski-Nisula, L., and Varrela, J., Orthodontic intervention in the early mixed dentition: A prospective, controlled study on the effects of the eruption guidance appliance, Am. J. Orthod. & Dentof Orthopedics, 133: 254-260, 2008.
21. Keski-Nisula, K., Keski-Nisula, L., Salo, H., Viopio, K., and Varrela, J., Dentofacial changes after orthodontic intervention with eruption guidance appliance in the early mixed dentition, Angle Orthod., 78: 324-331, 2008.
22. Leighton, B.C., The early signs of malocclusion, Trans. Europ. Orthod. Soc., 45th Cong: 353-368, 1969.
23. Lewis, S.J., and Lehman, I.A., Observations on growth changes of the teeth and dental arches, Dent. Cosmos, 71: 480-499, 1929.
24. Lieberman, M.A., Gazit, E., Fuchs, C. and Lilas, P., Mandibular dysfunction in 10-18 year old school children as related to morphological malocclusion, J. Oral Rehabil., 12: 209-214, 1985.
25. Little, R.M., Riedel, R.A. and Artun, J., An evaluation of changes in mandibular anterior alignment from 10 to 20 years postretention, Am. J. Orthod., 93: 423-428, 1988.
26. Luffingham, J.K. and Campbell, H.M., The need for orthodontic treatment, A pilot survey of 14 year old school children in Paisley, Scotland, Trans. Europ. Orthod. Soc., 50th Cong.: 259-267, 1974.
27. Mangovry, N.H., Gaafer, S.M., and Mostafa, Y.A., Mandibular crowding and periodontal disease, Angle Orthod., 57: 33-38, 1987.
28. Methenitou, S., Shein, B., Ramanathan, G. and Bergersen, E.O., The prevention of overbite and overjet development in the 3 to 8 year old by controlled nighttime guidance of incisal eruption: A study of 43 individuals, J. Pedodont., 14: 219-230, 1990.
29. Moorrees, C.F.A., The Dentition of the Growing Child, Harvard University Press, Cambridge, MA, 1959.
30. Poulton, D.R. and Aaronson, S.A., The relationship between occlusion and periodontal status, Am. J. Orthod., 47: 690-699, 1961.
31. Reitan, K., Tissue rearrangement during retention of orthodontically rotated teeth, Angle Orthod., 29: 105-113, 1959.
32. Sanchez-Woodworth, R.E., Katzberg, R.W., Tallents, R.H. and Guay, J.A., Radiographic assessment of temporomandibular joint pain and dysfunction in the pediatric age group, J. Dent. for Childr., 55: 278-281, 1988.
33. Sillman, J.H., Malocclusion in the deciduous dentition: Serial study from birth to five years, Am. J. Orthod. Oral Surg., 28: 197-209, 1942.
34. Silver, E.I., Forsyth orthodontic survey of untreated cases, Am. J. Orthod. and Oral Surg., 30: 635-659, 1944.
35. Simons, M.E. and Joondeph, D.R., Change in overbite: A ten-year postretention study. Am. J. Orthod., 64: 349-367, 1973.
36. Solberg, W.K., Bibb, C.A., Nordstrom, B.B. and Hansson, T.L., Malocclusion associated with temporomandibular joint changes in young adults at autopsy. Am. J. Orthod., 89: 328-330, 1986.
37. Van Bladeren, T.P.M., Tooth eruption and the development of the periodontal fibers. Trans. Europ. Orthod. Soc., 47th. Cong., 427-437, 1971.

*Dr. E. O. Bergersen is the inventor of the Nite-Guide® and Occlus-o-Guide® appliances and techniques.

Other Appliances Available From Ortho-Tain, Inc.

Occlus-o-Guide®	<i>For the 8-12 Year Old</i>
Ortho-T®	<i>For the Adult dentition</i>
Snore-Cure®	<i>To eliminate Nighttime Snoring</i>
Interim "G"™ Retainers	<i>Used between First and Second Phase Orthodontics</i>
Hawley-Form® Retainer	<i>The 5-minute customized chairside retainer</i>
Perfit Bumper®	<i>Creates space in any dentition</i>
Habit-Corrector®	<i>For the correction of oral habits</i>
Softee®	<i>A pre-orthodontic appliance for overbite and overjet correction</i>
Ortho-Tain® Positioner	<i>Used to finish and retain orthodontic treatment results</i>

Visit us: www.orthotain.com



RR-07 Box 11049 | Toa Alta, PR 00953-9900
phone: **800-541-6612** | fax: **847-446-7606**
www.orthotain.com | e-mail: **orthotain@aol.com**

©2010 ORTHO-TAIN,® INC. 999-9020-B Printed in U.S.A.